

Exogenous apelin ameliorates renal fibrosis in obstructive nephropathy

Masashi Nishida*, Yasuko Okumura, Tatsujiro Oka, Kentaro Toiyama, Seiichiro Ozawa, Toshiyuki Itoi and Kenji Hamaoka

Department of Pediatric Cardiology and Nephrology, Kyoto Prefectural University of Medicine Graduate School of Medical Science, Kawaramachi-Hirokoji, Kamigyo-ku, Kyoto 602-8566, Japan

ABSTRACT

Apelin is a vasoactive peptide isolated as a selective endogenous ligand of APJ receptor. The effects of the apelin/APJ system on renal fibrosis still remain unclear. We administered apelin in a unilateral ureteral obstruction (UUO) model of mouse and examined its effects on pathological changes related to renal fibrosis. The protein expression of APJ receptor in the UUO kidney was upregulated within 7 days following ureteral ligation. Treatment with apelin resulted in an attenuated renal interstitial fibrosis, a decreased myofibroblast accumulation, and a decreased tubular apoptosis, along with increased phospho-endothelial nitric oxide synthase (eNOS) and phospho-Akt protein expressions in the UUO kidney on day 7 after UUO without affecting blood pressure. When mice were treated with a NOS inhibitor, L-NAME, concomitantly with apelin, the degrees of renal fibrosis, myofibroblast accumulation, tubular apoptosis, and interstitial macrophage infiltration were all rather increased compared with the control mice with no treatment. These findings suggest that exogenous infusion of apelin ameliorates renal fibrosis in an early stage of obstructive nephropathy, at least in part, through the nitric oxide (NO)-dependent mechanism.

KEYWORDS: apelin, APJ receptor, nitric oxide, obstructive nephropathy, renal fibrosis, unilateral ureteral obstruction

INTRODUCTION

Apelin is a 36 amino-acid vasoactive peptide originally isolated from bovine stomach extracts as a selective endogenous ligand of orphan receptor, APJ [1]. Following studies have elucidated the roles of apelin/APJ system in human physiology including the regulation of cardiovascular function, with the distribution of apelin and APJ in tissues such as central nervous system, heart, lungs, and kidneys [2-5]. Importantly, apelin/APJ system has been shown to counteract to angiotensin II (Ang II) actions through the angiotensin II type 1 receptor (AT-1) in cardiovascular functions, although APJ receptor genetically has closest identity to the AT-1 receptor [6-8]. Recent reports have also elucidated the anti-fibrotic actions of apelin in cardiovascular system [9, 10]. In the kidney, apelin has glomerular hemodynamic functions that oppose to Ang II actions through the release of nitric oxide (NO) [11]. Additionally, our recent study has shown that mRNA expressions of apelin and APJ are upregulated in a mouse model of obstructive nephropathy, and that anti-fibrotic effect of angiotensin receptor blocker (ARB) in this model is, at least in part, due to increased apelin production and resulting NO release with ARB treatment [12]. However, the effect of exogenous apelin administration on the evolution of renal fibrosis has not been studied previously. In this study, we examined the effects of apelin administration on pathological changes related to renal fibrosis in a mouse model of obstructive nephropathy, and also studied on the possible contribution of NO production for these changes.

*Corresponding author
mnishida@koto.kpu-m.ac.jp

MATERIALS AND METHODS

Experimental protocol

Experiments were performed on male C57BL/6 mice (10-12 weeks, 20-24 g). These mice were subjected to a complete unilateral ureteral obstruction (UUO) as previously described [13]. Briefly, under sodium pentobarbital anesthesia, the middle portion of the left ureter was ligated and cut between the two ligated points. For western blot analyses of APJ receptor protein in the kidney, the mice were sacrificed at day 7 after surgery, and the obstructed kidneys were harvested and subjected to the studies. For histological studies, western blotting for phosphorylated endothelial nitric oxide synthase (p-eNOS) and phosphorylated Akt (p-Akt), and measurement of collagen content of the kidney, a 100 μ l osmotic minipumps (model 1007D, Alzet Osmotic pumps, Durect Co., Cupertino, CA, USA) was implanted subcutaneously according to the manufacturer's instructions at the time of UUO, and these mice received 7 days infusions of (Pyr1)-apelin-13 (Bachem Feinchemikalien AG, Bubendorf, Switzerland) (2 mg/kg/day) dissolved in saline or saline only with these minipumps as previously described [8]. The mice were divided into a total of three groups as follows: (a) saline; (b) apelin; (c) apelin plus L-NAME (Tocris Cookson Inc., Ellisville, MO, USA) (100 mg/l in drinking water). At day 7 after surgery, the mice were sacrificed, and the obstructed kidneys were harvested and subjected to the studies. The systolic blood pressure of the mice was measured by the tail-cuff method using MK-2000ST (Muromachi Kikai, Inc., Tokyo, Japan) at day 0, day 3, and day 7 after UUO. The experimental protocols were performed according to the regulations of the Kyoto Prefectural University of Medicine Animal Care Committee.

Western blot analysis

Western blot analysis was performed as previously described [9]. In brief, the obstructed kidneys were lysed in lysis buffer containing 20 mM Tris-HCl pH 8.0, 150 mM NaCl, 1 mM EDTA, 100 mM NaF, 1 mM Na_3VO_4 , and 1% proteinase inhibitor (Sigma-Aldrich Japan K.K., Tokyo, Japan). Lysates were centrifuged at 10,000 g for 10 min, and supernatants (30 μ g protein/lane) were separated by SDS-PAGE on a 10% acrylamide gel.

Gels were electroblotted onto a nitrocellulose membrane (GE Healthcare UK Ltd., Little Chalfont, United Kingdom). The membranes were blocked with 2% nonfat dry milk and were incubated with either polyclonal rabbit anti-APJ receptor (Santa Cruz Biotechnology Inc., Santa Cruz, CA, USA), polyclonal rabbit anti-phospho-eNOS (Cell Signaling Technology Inc., Danvers, MA, USA), polyclonal rabbit anti-phospho-Akt (Cell Signaling Technology Inc.), or polyclonal goat anti- α -tubulin (Santa Cruz Biotechnology Inc.) overnight at 4°C. The membranes were then incubated with horseradish peroxidase-conjugated goat anti-rabbit IgG (Cell Signaling Technology Inc.) to detect APJ receptor, phospho-eNOS, and phospho-Akt, and with horseradish peroxidase-conjugated donkey anti-goat IgG (Santa Cruz Biotechnology Inc.) to detect α -tubulin, developed with ECL Plus Detection System (GE Healthcare UK Ltd.), and captured on X-ray film. The signals were scanned and semiquantitated using the image-J program.

Histological study

For histological examinations, the kidneys were fixed with 4% buffered paraformaldehyde for 6 hours, embedded in paraffin, and sectioned transversely with a thickness of 4 μ m. For immunostaining for α -smooth muscle actin (α -SMA), sections were incubated with monoclonal mouse anti-human α -SMA (DAKO, Carpinteria, CA, USA) following the manufacturer's protocol [14]. To detect apoptotic cells, the terminal deoxy transferase uridine triphosphate nick end-labeling (TUNEL) method was employed using ApopTag[®] Peroxidase *In Situ* Apoptosis Detection Kit (Intergen Co., Purchase, NY, USA) following the manufacturer's protocol. To detect infiltrating macrophages, sections were incubated with monoclonal rat anti-mouse F4/80 (Selotec, Oxford, United Kingdom) for 1 hour at room temperature, followed by standard ABC immunostaining using ABC-alkaline phosphatase kit (Vector, Burlingame, CA, USA) [13]. A standard point-counting method was used to quantitate the collagen fractional volume in the renal cortical interstitium on Masson trichrome-stained sections (magnification, $\times 400$), as previously described [13]. The index of interstitial collagen fractional volume was defined as the number of trichrome-positive points in every 1000 points evaluated. The expression of α -SMA

in the cortical interstitial area was assessed semiquantitatively by immunoreactivity for α -SMA as previously described [14]. Labeling index for TUNEL was determined by counting labeled nuclei, and macrophage infiltration was determined by enumerating F4/80-positive cells, respectively, within the cortical interstitium in 10 randomly selected cortical fields under magnification ($\times 400$), and the numbers were averaged for each field [14].

Collagen content

The amount of hydroxyproline in the renal cortex was measured as an index of collagen content as previously described [15]. Briefly, pieces of renal cortex for the hydroxyproline assay were weighed and snap-frozen in liquid nitrogen at sacrifice. After being hydrolyzed in 1 mL of 6 N hydrochloric acid and neutralized with sodium hydroxide, the concentrations of hydroxyproline of the samples were determined by high-performance liquid chromatography (HPLC) using HPLC system 800 series (JASCO Co., Tokyo, Japan).

Statistical analysis

Data are presented as means \pm SEM. Statistical analysis was performed by ANOVA for multiple comparison analysis, and by Mann-Whitney's U test for those between two groups. Statistical significance was defined as $P < 0.05$.

RESULTS

The protein expression of APJ receptor in the UUO kidneys

APJ receptor protein expression in the UUO kidneys at day 7 after UUO assessed by western blotting was significantly increased compared with that in nonobstructed kidneys (NOB) at day 0 (the ratio to α -tubulin protein; 0.41 ± 0.06 vs. 0.70 ± 0.04 , $P < 0.01$, $N = 5$) (Figure 1A, 1B).

Effect of apelin administration on blood pressure

No significant difference was observed in the systolic blood pressure between control (saline) and apelin-treated mice either on day 0 (before UUO), day 3, or day 7 after UUO (day 0; 109 ± 5 vs. 110 ± 5 mmHg, NS; day 3; 101 ± 5 vs. 98 ± 5 , NS; day 7; 103 ± 4 vs. 98 ± 3 , NS, $N=6$ in each group).

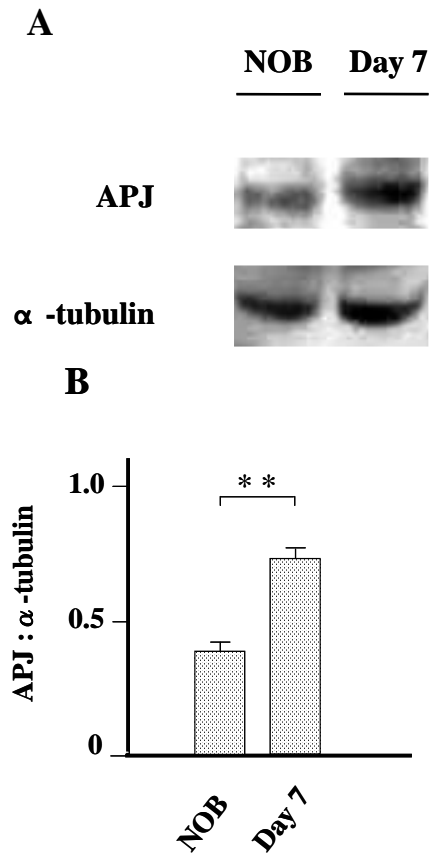


Figure 1. The protein expression of APJ receptor in the UUO kidneys. Whole kidney lysates from obstructed kidneys at day 7 after UUO, and from non-obstructed normal kidney, were examined for APJ receptor protein expression by Western blot analysis (A), and quantitatively analysed as the ratio to α -tubulin protein levels (B). Data are expressed as means \pm SEM. ** $P < 0.01$ vs. NOB. NOB, non-obstructed kidney.

Effect of apelin administration on renal fibrosis

Treatment with apelin resulted in a significant decrease in interstitial collagen index at day 7 after UUO compared with that of control (67 ± 3 vs. $42 \pm 4 / 1000$ points, $P < 0.01$, $N = 8$ in control and $N = 9$ in apelin group) (Figure 2A, 2B, 3A). The collagen content in renal tissue assessed by HPLC was also significantly lower in mice treated with apelin compared to that in the control (hydroxyproline; 8.0 ± 0.4 vs. 6.3 ± 0.3 nmol/mg wet weight, $P < 0.01$, $N = 8$ in control and $N = 7$ in apelin group) (Figure 3B). However, treatment with apelin + L-NAME resulted in significant increases in both interstitial collagen index and collagen content compared to mice treated with

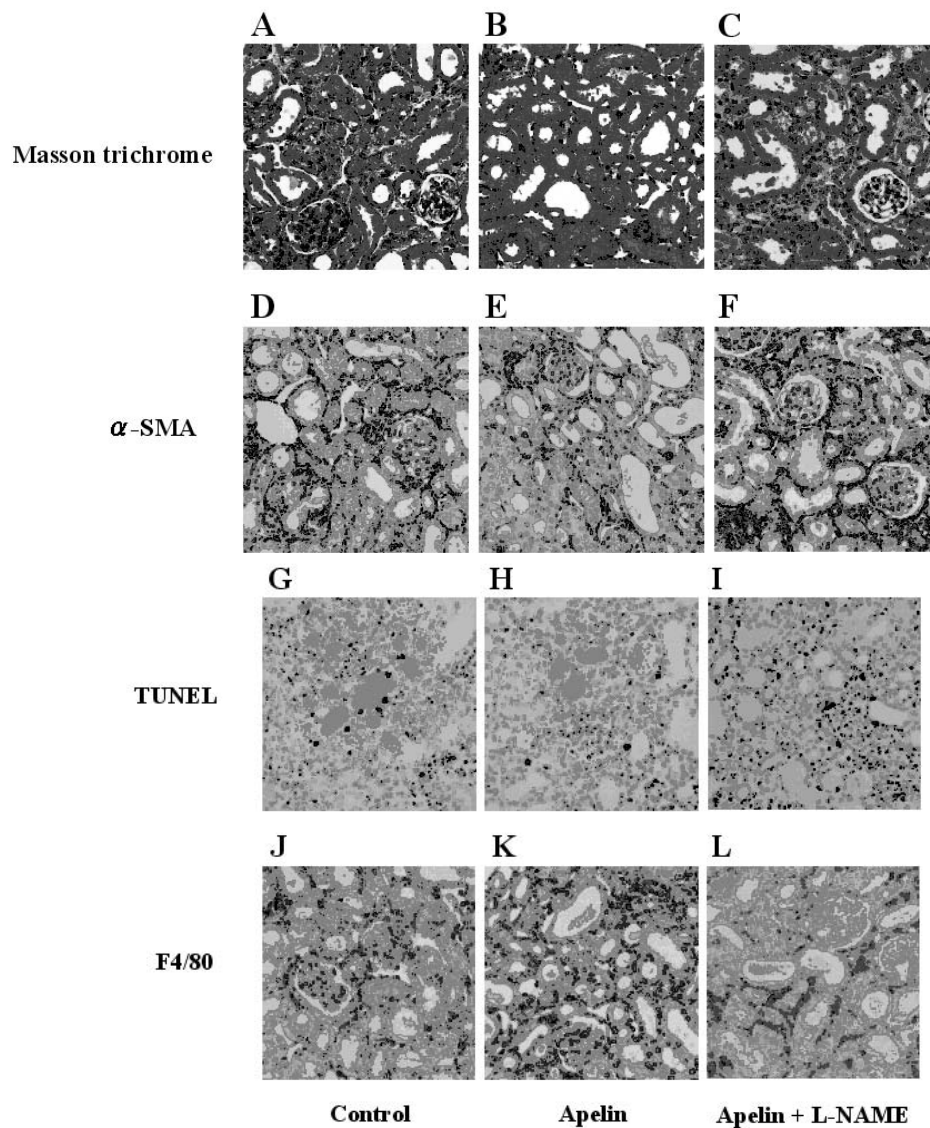


Figure 2. Histological assessment of interstitial fibrosis, myofibroblast accumulation, apoptosis, and macrophage infiltration in the UUO kidneys. Masson trichrome staining in control mice (A), in mice treated with apelin (B), and in mice treated with apelin + L-NAME (C); Immunohistochemical demonstration of myofibroblasts with anti- α -smooth muscle actin (α -SMA) antibody in control mice (D), in mice treated with apelin (E), and in mice treated with apelin + L-NAME (F); Detection of apoptotic cells (TUNEL-positive cells) in control mice (G), in mice treated with apelin (H), and in mice treated with apelin + L-NAME (I); Immunohistochemical demonstration of macrophages with anti-F4/80 antibody in control mice (J), in mice treated with apelin (K), and in mice treated with apelin + L-NAME (L) at day 7 after UUO. Original magnification, $\times 400$.

apelin only, and also significantly increased compared with those in the control group with no treatment (collagen index; 83 ± 3 in apelin + L-NAME group, $P < 0.01$ vs. apelin group, $P < 0.05$ vs. control, $N = 8$; hydroxyproline; 9.3 ± 0.4 in apelin + L-NAME group, $P < 0.01$ vs. apelin group, $P < 0.05$ vs. control, $N = 7$) (Figure 2C, 3A, 3B).

Effect of apelin administration on myofibroblast accumulation

The degree of interstitial myofibroblast accumulation assessed by immunostaining for α -SMA was significantly lower in mice treated with apelin compared to that in the control at day 7 after UUO (α -SMA score; 1.89 ± 0.09 vs. 1.32 ± 0.08 , $P < 0.01$,

N = 8 in control and N = 9 in apelin group) (Figure 2D, 2E, 3C). However, treatment with apelin + L-NAME resulted in a significant increase in interstitial myofibroblast accumulation compared with mice treated with apelin only (2.32 ± 0.13 in apelin + L-NAME group, $P < 0.01$ vs. apelin group, N = 8) (Figure 2F, 3C).

Effect of apelin administration on tubular apoptosis

TUNEL-positive apoptotic cells were observed in the tubular epithelium at day 7 after UUO (Figure 2G). The number of TUNEL-positive cells

was significantly decreased in mice treated with apelin compared with that in the control (8.2 ± 0.5 vs. $3.7 \pm 0.05 / \times 400$ field, $P < 0.01$, N = 8 in control and N = 9 in apelin group) (Figure 2H, 3D). However, by the treatment with apelin + L-NAME, the number of TUNEL-positive cells resulted in significant increases compared with that in mice treated with apelin only, and also a significant increase compared to the control (11.2 ± 0.7 in apelin + L-NAME group, $P < 0.01$ vs. apelin group, $P < 0.05$ vs. control, N = 8) (Figure 2I, 3D).

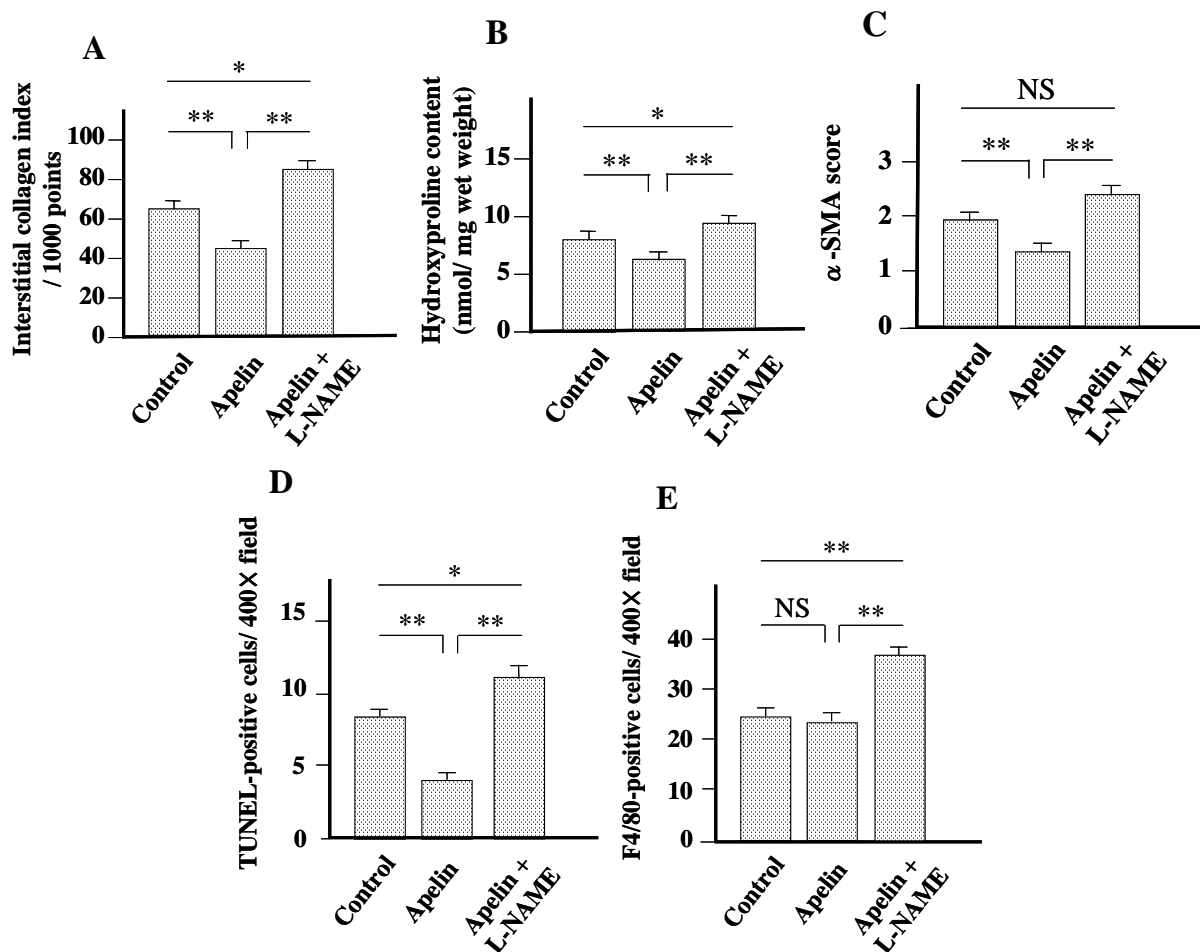


Figure 3. Quantitative analysis of interstitial collagens, interstitial myofibroblasts, apoptotic cells, and interstitial macrophage infiltration in the UUO kidneys. Interstitial collagen index assessed by point-counting method on Masson trichrome-stained sections (A), hydroxyproline content in renal tissue assessed by high-performance liquid chromatography (HPLC) (B), interstitial myofibroblast accumulation assessed by α -SMA score (C), number of apoptotic cells (TUNEL-positive cells) (D), and number of macrophages (F4/80-positive cells) infiltrating to the interstitium (E), in control mice, in mice treated with apelin, and in mice treated with apelin + L-NAME at day 7 after UUO. Data are expressed as means \pm SEM. * $P < 0.05$. ** $P < 0.01$. NS, not significant.

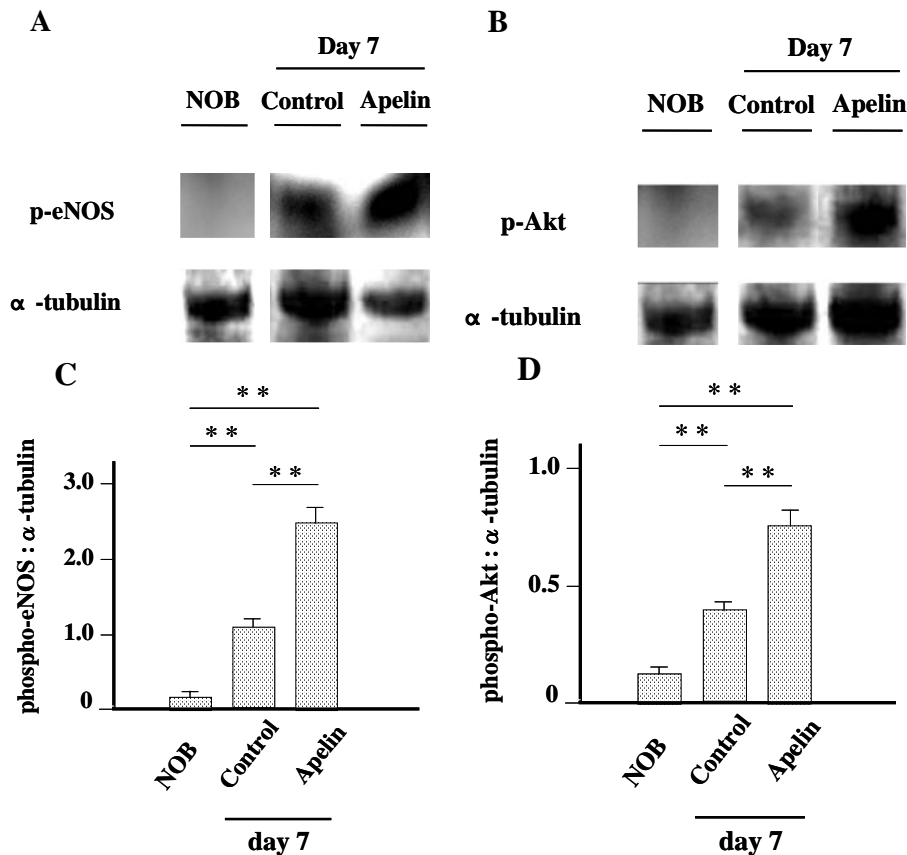


Figure 4. Effect of apelin administration on phospho-eNOS and phospho-Akt protein expressions in the UUO kidneys. Whole kidney lysates from obstructed kidneys at day 7 after UUO with or without apelin treatment, and from non-obstructed normal kidney, were examined for phosphorylated endothelial nitric oxide synthase (p-eNOS) protein expressions (A) and phosphorylated Akt (p-Akt) protein expressions (B) by Western blot analysis, and quantitatively analysed as the ratio to α -tubulin protein for p-eNOS (C) and p-Akt (D). Data are expressed as means \pm SEM. ** $P < 0.01$. NOB, non-obstructed kidney.

Effect of apelin administration on interstitial macrophage infiltration

No significant change was observed by treatment with apelin in the number of F4/80-positive interstitial macrophages at day 7 after UUO compared with the control (24.1 ± 1.4 vs. $23.6 \pm 1.5 / \times 400$ field, NS, $N = 8$ in control and $N = 9$ in apelin group) (Figure 2J, 2K, 3E). However, treatment with apelin + L-NAME resulted in a significant increase in the number of F4/80-positive interstitial macrophages compared with mice treated with apelin only, and also a significant increase compared with the control (37.4 ± 1.4 in apelin + L-NAME group, $P < 0.01$ vs. apelin group, $P < 0.01$ vs. control, $N = 8$) (Figure 2L, 3E).

Effect of apelin administration on phospho-eNOS and phospho-Akt protein expressions

Both phosphorylated eNOS (p-eNOS) and phosphorylated Akt (p-Akt) protein expressions in the UUO kidneys assessed by western blotting were increased at day 7 after UUO compared with those in NOB (day 0) (the ratio to α -tubulin protein; p-eNOS; 0.17 ± 0.02 vs. 1.12 ± 0.11 , $P < 0.01$, $N = 6$ in each group; p-Akt; 0.13 ± 0.02 vs. 0.41 ± 0.03 , $P < 0.01$, $N = 6$ in each group). Furthermore, treatment with apelin significantly accelerated both p-eNOS and p-Akt protein expressions at day 7 after UUO compared with those in control (day 7) (p-eNOS; 2.43 ± 0.14 , $P < 0.01$ vs. control, $N = 6$; p-Akt; 0.75 ± 0.03 , $P < 0.01$ vs. control, $N = 6$) (Figure 4A, 4B, 4C, 4D).

DISCUSSION

In a previous study, we have found that mRNA expressions of both apelin and APJ receptors are upregulated in the UUO kidney at day 7 after UUO [12]. In this study, we examined protein expression of APJ receptor in the UUO kidney, and found that APJ receptor protein is also increased at day 7 after UUO, which was consistent with our previous result. On the bases of this finding showing increased APJ receptor protein in the UUO kidney, we next examined the effects of exogenous apelin administration during 7 days following UUO on the obstructed kidneys in mouse UUO model.

In this study, treatment with apelin in the UUO model resulted in an attenuated renal interstitial fibrosis, a decreased myofibroblast accumulation as well as a decreased tubular apoptosis, indicating a tissue protective effect of apelin administration in the UUO kidney. In our previous study, we have shown that increased NO production through the activation of apelin/APJ/Akt/eNOS pathway contributes to the alleviative effect of ARB treatment for UUO-induced renal fibrosis [12]. Several previous studies have also elucidated the role of increased NO bioavailability to improve renal damage including fibrosis and apoptosis in the UUO kidney [16, 17]. Therefore, as a mechanism for this tissue protective action of apelin in the present study, we hypothesized an effect of NO production by the apelin administration, and examined phosphorylations of eNOS and Akt proteins in the UUO kidney. The extent of phospho-eNOS and phospho-Akt protein expressions were both significantly increased in apelin-treated mice compared with the control at day 7 after UUO, suggesting that, although systemic blood pressure was not affected by the dose of apelin used in our study, the production of NO in the UUO kidney may be increased by the treatment with apelin. Furthermore, when mice were treated with a nitric oxide synthase (NOS) inhibitor, L-NAME, concomitantly with apelin, these effects of apelin on the obstructed kidneys were all absent, and the degrees of renal fibrosis and myofibroblast accumulation, and the number of apoptotic tubular cells as well as the number of macrophages infiltrating to the interstitium were all rather increased compared with the control mice.

These results, along with the increased signalling of NO production, suggest that the tissue protective effect of apelin treatment during 7 days following ureteral ligation observed in our study can be, at least in part, through the NO-dependent mechanism via apelin/APJ/Akt/eNOS pathway.

In summary, we have shown for the first time that exogenous infusion of apelin ameliorates pathological changes related to renal fibrosis in an early stage of mouse obstructive nephropathy, at least in part, through the NO-dependent mechanism. Although further studies regarding the role of apelin/APJ system in the process of renal fibrosis are considered necessary, our results evoke potential for possible therapeutic target of apelin/APJ system for renal fibrosis in the future.

ACKNOWLEDGEMENTS

This study was supported in part by a Grant-in-Aid for Scientific Research C from the Japan Society for the Promotion of Science (19591263).

CONFLICT OF INTEREST STATEMENT

The authors declare that there are no conflicts of interest.

REFERENCES

1. Tatemoto, K., Hosoya, M., Habata, Y., Fujii, R., Kakegawa, T., Zou, M. X., Kawamata, Y., Fukusumi, S., Hinuma, S., Kitada, C., Kurokawa, T., Onda, H. and Fujino, M. 1998, *Biochem. Biophys. Res. Commun.*, 251, 471-476.
2. Kawamata, Y., Habata, Y., Fukusumi, S., Hosoya, M., Fujii, R., Hinuma, S., Nishizawa, N., Kitada, C., Onda, H., Nishimura, O. and Fujino, M. 2001, *Biochim. Biophys. Acta.*, 1538, 162-171.
3. Kleinz, M. J., Skepper, J. N. and Davenport A. P. 2005, *Regul. Pept.*, 126, 233-240.
4. Kleinz, M. J. and Davenport, A. P. 2005, *Pharmacol. Ther.*, 107, 198-211.
5. Falcao-Pires, I. and Leite-Moreira, A. F. 2005, *Rev. Port. Cardiol.*, 24, 1263-1276.
6. O'Dowd, B. F., Heiber, M., Chan, A., Heng, H. H., Tsui, L. C., Kennedy, J. L., Shi, X., Petronis, A., George, S. R. and Nguyen, T. 1993, *Gene*, 136, 355-360.

7. Ishida, J., Hashimoto, T., Hashimoto, Y., Nishiwaki, S., Iguchi, T., Harada, S., Sugaya, T., Matsuzaki, H., Yamamoto, R., Shiota, N., Okunishi, H., Kihara, M., Umemura, S., Sugiyama, F., Yagami, K., Kasuya, Y., Mochizuki, N. and Fukamizu, A. 2004, *J. Biol. Chem.*, 279, 26274-26279.
8. Chun, H. J., Ali, Z. A., Kojima, Y., Kundu, R. K., Sheikh, A. Y., Agrawal, R., Zheng, L., Leeper, N. J., Pearl, N. E., Patterson, A. J., Anderson, J. P., Tsao, P. S., Lenardo, M. J., Ashley, E. A. and Quertermous, T. 2008, *J. Clin. Invest.*, 118, 3343-3354.
9. Fukushima, H., Kobayashi, N., Takeshima, H., Koguchi, W. and Ishimitsu, T. 2010, *J. Cardiovasc. Pharmacol.*, 55, 83-88.
10. Siddiquee, K., Hampton, J., Khan, S., Zadory, D., Gleaves, L., Vaughan, D. E. and Smith, L. H. 2011, *J. Hypertens.*, 29, 724-731.
11. Hus-Citharel, A., Bouby, N., Frugière, A., Bodineau, L., Gasc, J. M. and Llorens-Cortes, C. 2008, *Kidney Int.*, 74, 486-494.
12. Nishida, M., Okumura, Y., Oka, T., Toiyama, K., Ozawa, S., Itoi, T. and Hamaoka, K. 2012, *Nephron Extra*, 2, 39-47.
13. Nishida, M., Fujinaka, H., Matsusaka, T., Price, J., Kon, V., Fogo, A. B., Davidson, J. M., Linton, M. F., Fazio, S., Homma, T., Yoshida, H. and Ichikawa, I. 2002, *J. Clin. Invest.*, 110, 1859-1868.
14. Fujinaka, H., Miyazaki, Y., Matsusaka, T., Yoshida, H., Fogo, A. B., Inagami, T. and Ichikawa, I. 2000, *Kidney Int.*, 58, 2018-2027.
15. Miyazawa, S., Hotta, O., Doi, N., Natori, Y., Nishikawa, K. and Natori, Y. 2004, *Kidney Int.*, 65, 2228-2237.
16. Miyajima, A., Chen, J., Poppas, D. P., Vaughan, E. D. Jr. and Felsen, D. 2001, *Kidney Int.*, 59, 1290-1303.
17. Ito, K., Chen, J., Seshan, S. V., Khodadadian, J. J., Gallagher, R., El Chaar, M., Vaughan, E. D. Jr., Poppas, D. P. and Felsen, D. 2005, *Kidney Int.*, 68, 515-528.