

Toxicity assessment of a new polyherbal medicinal preparation in rats

Rania H. Abdou¹, Sherif Y. Saleh², Noha S. Abdelnaeim³ and Waleed F. Khalil^{4,*}

¹Department of Forensic Medicine and Toxicology; ²Department of Biochemistry;

³Department of Clinical Pathology; ⁴Department of Pharmacology;

Faculty of Veterinary Medicine, University of Suez Canal, Ismailia 41522, Egypt.

ABSTRACT

The tradition of using herbal preparations as a remedy is becoming more pronounced year after year as it is a cheaper alternative medication with lower undesirable effects. Brown algae are a group of seaweeds that has a promising pharmaceutical and biomedical capability in medicine. *Cystoseira trinodis* (*C. trinodis*) and *Sargassum dentifolium* (*S. dentifolium*) are brown algae belonging to the class Phaeophyceae. Previous studies have demonstrated their hepatoprotective effects and wound healing activities. The current study is a preliminary safety study aiming to investigate any possible toxic effects of an experimental polyherbal preparation (EMP) consisting of two brown algae (*S. dentifolium* and *C. trinodis*) plus three plants (garlic, liquorice and ginger) intended to be used orally as a hepatosupportive and immunostimulant supplement. In this study forty Wistar male rats, about two months old, were used to evaluate the acute, subchronic and the chronic adverse effects of the EMP preparation. In the acute study, single oral dose of 5 gm EMP/kg body weight was administered daily for one week. Subchronic and chronic studies were carried out using 250 and 500 mg of the EMP/kg body weight daily for 1 and 3 months, respectively. LD₅₀, haematological, biochemical and redox markers were measured, then histopathological examinations were performed. Results revealed that, administration of EMP in

high doses for long duration provoked some adverse effects on liver and kidney; these adverse effects were in dose- and time-dependent manners. Further investigations are required to determine the safest dose and duration, as well as the ideal ratio between the EMP constituents.

KEYWORDS: toxicity assessment, safety study, brown algae, polyherbal natural extract, median lethal dose.

INTRODUCTION

The use of synthetic compounds in medicine has been limited by toxicity and safety and may result in potential health hazards [1]. Recently, many efforts were made to discover natural products that have the ability to prevent and cure illness inducing no or minimal side effects [2]. Considering the cost and side effects, usage of herbal remedies is becoming more pronounced as it is a cheaper alternative with lower undesirable effects [3, 4]. Herbs and plants contain numerous bioactive compounds that have beneficial medical applications and represent a starting point in the manufacturing of over 50% of currently used drugs [5].

In the last few decades, there is a great interest in drugs from marine algae (seaweeds). These algae are of big nutritional value due to their high content of carotenoids, proteins, essential fatty acids, vitamins and minerals [6]. Also, marine algae are considered as essential sources for many bioactive products which were used in

*Corresponding author: wk@vet.suez.edu.eg

the treatment of various diseases such as scabies, asthma, arteriosclerosis, heart disease, eczema, ulcers and cancer [7].

Brown algae are a group of seaweeds that has a promising pharmaceutical and biomedical capability in medicine [8, 9].

Cystoseira trinodis (*C. trinodis*) is one of the brown algae that belongs to the class Phaeophyceae [10]. A previous study [7] demonstrated the hepatoprotective effects of *Sargassum dentifolium* (*S. dentifolium*) (class Phaeophyceae) ethanolic extract against carbon tetrachloride-induced hepatitis in rats. In another study by the same researchers, a crude extract consisting of three medicinal plants (garlic, liquorice and ginger) in addition to the brown algae (*C. trinodis*) have been used as a wound healer topical remedy in healthy and alloxan-induced diabetic rats and revealed excellent healing activity in chronic ischemic wounds [11]. Based on these results, our research staff members prepared a medicinal preparation of two brown algae (*S. dentifolium* and *C. trinodis*) with three plants (garlic, liquorice and ginger) to be used orally as a hepatosupportive and immunostimulant supplement for human and animal remedy. Therefore, the current study is a preliminary safety study aiming to investigate any toxic effects of this herbal combination. Hence, haematological, biochemical and redox markers were measured in control and treated rats, then histopathological examinations were performed to achieve our goal.

MATERIALS AND METHODS

Experimental medicinal preparation

The experimental medicinal preparation (EMP) consisted of 2 brown algae, *S. dentifolium* and *C. trinodis* (collected from the Egyptian coast of the Red Sea), in addition to three medicinal plants (garlic, liquorice and ginger); these ingredients were selected according to [12]. The plants used in this study were obtained from the local market.

Preparation of the extract

Samples of algae were cleaned by washing with sea water, tap water, then distilled water to get rid of wastes. After complete dryness of algae and plants in hot air oven at 45 °C, each plant was

extracted separately. The dried plants were crushed and soaked in 70% ethanol for 48 hrs to prepare the ethanolic extract, and the extract was filtered and then evaporated under negative pressure using rotavapour (RE111, BUCHI Corporation, DE, USA) at 40 °C to eliminate ethanol. Extracts were kept in dark containers at 4 °C until use.

Oral LD₅₀ determination

Twelve male Wistar rats were used to determine the EMP median lethal dose (LD₅₀). Graduated doses were administered orally by stomach tube. Rats were observed for appearance of toxicity signs and mortality for 24 h after dosing. The modified up-and-down technique was used to determine the LD₅₀ of the EMP according to [13]. LD₅₀ was estimated using AOT425 statistical program (Version 1.0, Westat, NW, Washington DC, USA).

Experimental animals

Forty Wistar male rats, about two months old, weighing 150-160 g were used in the current study. The animals were purchased from the Animal House Colony of the National Research Center, Dokki, Cairo, Egypt. The animals were allowed for acclimatization for one week before running of the experiment. Rats were fed commercial diet and allowed free water access. This study was done according to the guidelines of the Scientific Ethical Committee, Faculty of Veterinary Medicine, Suez Canal University.

Groups and experimental design

Three experiments were conducted to evaluate the acute, subchronic and the chronic adverse effects of the EMP preparation.

a) Acute study: Ten rats were divided into two groups (5 animals each); the control group was administered with physiological saline orally, while the treated group received single oral dose of 5 gm EMP/kg body weight. This study was carried out for one week.

b) Subchronic study: Fifteen rats were grouped into 3 groups (5 rats each); control group (administered physiological saline orally) and two treated groups. The 1st treated group received 250 mg of the EMP/kg body weight/day for 30 days (low dose), while the 2nd treated group was

given 500 mg of the EMP/kg body weight/day for 30 days (high dose).

c) Chronic study: Another 15 rats were used in this experiment; rat grouping and dose regimen were same as the subchronic experiment but the treatment continued for 3 months instead of one month.

All treatments were orally administered using stomach tube. The low and high doses were decided to be one twentieth and one tenth of the calculated LD₅₀ (250 and 500 mg EMP/kg body weight, respectively).

Blood and tissue sampling

Blood samples were obtained from the retro-orbital plexus and transferred into two types of tubes. The first type of tubes contained EDTA and were used for the hematological analysis, while the second type of tubes (without anticoagulant) were kept at room temperature then centrifuged at $1200 \times G$ (gravitational force) for 10 min to prepare the sera. These sera were used for assessment of biochemical parameters related to liver and kidney integrity, oxidative stress biomarkers and inflammatory markers. Rats were then sacrificed by cervical dislocation under a light anaesthesia, and then the liver and kidneys were detached and washed several times with normal saline. Part of the tissues was used for antioxidant/oxidative stress biomarkers evaluation and the rest was reserved in 10% formalin buffer for histopathological examinations.

Chemicals

Kits of alanine aminotransferase (ALT), aspartate aminotransferase (AST), albumin, urea, creatinine, reduced glutathione (GSH) and malondialdehyde (MDA) were purchased from Biodiagnostics Co. (Cairo, Egypt). C-reactive protein (CRP), tumor necrosis factor (TNF) and α 1-fetoprotein (AFP) levels were evaluated using diagnostic kits (Roche Diagnostics, Cairo, Egypt).

Biochemical examinations

Serum AST and ALT were estimated according to [14]. Serum albumin level was assessed by the method of [15]. Serum renal products: creatinine was evaluated according to [16] and urea was measured according to [17]. MDA was evaluated

according to [18]. GHS and GSH were assessed according to [19]. AFP, CRP and TNF were estimated according to [20], [21] and [22], respectively.

Histopathological examinations

The formalin-preserved liver and kidneys specimens were dehydrated gradually using ethanol, cleared in xylene, then embedded in paraffin wax [23]. Several tissue sections (4 μ m thickness) were obtained for routine histopathological examination and stained with haematoxylin and eosin (H&E) dyes.

Semiquantitative scoring

Scores of hepatic and renal lesions were performed according to [24]. For each animal, lesions in 10 randomly selected fields from each slide were scored and averaged. The score scale was; 0 for normal histopathology; 1 \leq 25%; 2 for 26-50%; 3 for 51-75% and 4 for 76-100% pathologic lesions. The assessment of hepatic lesions was based on the presence of hepatic degeneration, leukocytic infiltration and proliferation of bile ducts. Renal tubular degeneration and glomerular proliferation were used for assessment of the renal lesions.

Statistical analysis

All data were expressed as mean \pm standard deviation (SD) and were analyzed using Students "t" test according to [25]. $P \leq 0.05$ was accepted as significant.

RESULTS

Oral LD₅₀ result

No deaths or signs of toxicity were observed after oral administration of EMP up to 5 g/kg b.wt. within 24 h. Furthermore, no signs of delayed toxicity appeared for additional 14 days.

Blood parameters

There were no significant differences in hematological parameters between control and treated groups (Table 1).

Biochemical parameters

The effects of EMP on serum transaminases, urea, creatinine and albumin levels are showed in Table 2.

Table 1. Blood parameters in control and different treated groups.

Parameters	Experimental groups							
	Acute study		Subchronic study			Chronic study		
	Control	Treated	Control	Low dose	High dose	Control	Low dose	High dose
RBCs ($10^6/\mu\text{L}$)	7.61 \pm 0.63	8.43 \pm 0.65	8.76 \pm 0.55	8.03 \pm 0.33	8.69 \pm 0.95	8.16 \pm 1.23	8.15 \pm 0.42	7.93 \pm 0.55
Hb (g/dL)	12.7 \pm 0.80	14.1 \pm 0.97	14.37 \pm 0.59	14.1 \pm 0.42	14.9 \pm 0.85	12.9 \pm 1.43	14.3 \pm 0.90	13.7 \pm 1.42
HCT%	38.1 \pm 3.07	40.8 \pm 2.90	40.6 \pm 1.87	41.6 \pm 1.57	44.7 \pm 3.06	39.8 \pm 4.25	44.7 \pm 2.21	41.7 \pm 2.04
MCV fL	49.8 \pm 2.17	50.8 \pm 3.21	46.5 \pm 4.08	53.7 \pm 7.05	49.4 \pm 6.50	49.8 \pm 1.59	54.7 \pm 3.65	51.4 \pm 3.56
WBCs ($10^3/\mu\text{L}$)	12.2 \pm 2.56	10.0 \pm 2.08	16.0 \pm 3.29	12.0 \pm 4.66	13.9 \pm 3.34	14.1 \pm 3.16	16.7 \pm 4.22	17.2 \pm 4.71
BP ($10^3/\mu\text{L}$)	810 \pm 233	757 \pm 236	983 \pm 95.5	919 \pm 92.6	956 \pm 121	935 \pm 127	866 \pm 168	811 \pm 147

RBCs, red cell count; Hb, hemoglobin; HCT, haematocrit; MCV, mean corpuscular volume; WBCs, white blood cells; BP, blood platelets. Data are expressed as means \pm SD ($n = 5$). Student's t-test was applied comparing each treatment with its control group; a probability value ≤ 0.05 was considered statistically significant.

Only the albumin concentration and the AST activity were significantly increased ($p \leq 0.05$) in the treated groups of the acute study and of the chronic study.

There was a significant increase ($p \leq 0.05$) in AST activity in the rats that received the high dose of EMP for 3 months (the chronic experiment). Also, the albumin concentration was significantly increased ($p \leq 0.05$) in the sera of the rats that were given single oral dosing of EMP (the acute study). The rest of the tested biochemical parameters were not affected by the EMP oral administration.

Inflammatory markers

While there was no change in AFP levels within the acute study rats, there were significant increases in AFP levels in both high dose-treated groups of the subchronic and chronic experiments. CRP and TNF were not significantly affected in all treated groups compared with the control groups (Table 2).

Oxidant and antioxidant parameters

In comparison with normal control groups, a significant decrease in hepatic GSH and a significant increase in hepatic MDA were observed after three months of treatment with a high dose of EMP (Table 3).

Histopathological findings

Liver of normal control rats showed normal histology of hepatic lobules, hepatic areas, central veins and polyhedral hepatic cells (Figure 1-a). On the other hand, all livers that received single high dose of EMP (5 gm/kg) showed mild vacuolation, mild hyperplasia of bile ducts and mild to moderate focal mononuclear cell infiltration around hepatic areas (Figure 1-b). Whereas livers that received the low dose of EMP for 1 month, showed mild focal hyperplasia of bile ducts along with scanty lymphocytic infiltrations (Figure 1-c). The high dose of EMP for 1 month revealed moderate to severe mononuclear leucocytic (mainly lymphocytes and macrophages) infiltrations (Figure 1-d). The livers that received the low dose of EMP for 3 months showed mild to moderate multifocal hyperplasia of bile ducts along with scanty lymphocytic infiltrations around hepatic areas (Figure 1-e). Livers treated with high dose

of EMP for 3 months showed moderate hyperplasia of bile ducts, mononuclear leucocytic infiltrations with lymphocytes, macrophages and fibroblasts, in addition to a focal hydropic degeneration of hepatocytes (Figure 1-f).

Kidney of normal control rats showed normal histology of nephrons (glomeruli and renal tubules). The renal glomeruli displayed the normal Bowman's capsule, Bowman's space and glomerular capillaries, while the renal tubules demonstrated the healthy proximal and distal convoluted tubules with a few collecting tubules in between (Figure 2-a). Acute exposure to a single dose of EMP resulted in a mild focal hyaline cast inside some renal tubules (Figure 2-b). The low dose of EMP for 1 month showed mild expansion of some glomeruli and normal histology of renal tubules (Figure 2-c). The high dose of EMP induced a mild expansion of some glomeruli with mild degeneration of renal tubules (Figure 2-d). Chronic low dose treatment for 3 month showed mild expansion of some glomeruli with normal renal tubular epithelium (Figure 2-e). At the high dose treatment for 3 months, the kidneys showed moderate expansion of some glomeruli with vacuolation and proliferation of capillary endothelium. Focal, mild degeneration of renal tubules with the presence of homogenous eosinophilic materials in their lumen was also observed (Figure 2-f).

Result of histopathological lesion scoring

Although the lesion scoring revealed dose- and time-dependent lesions in liver and kidneys, the lesion scores of both liver and kidney showed no significant difference between all treated groups and their control groups (Figure 3).

DISCUSSION

The present study was carried out to assess the possible toxic effects of a new medicinal preparation consisting of brown algae (*S. dentifolium* and *C. trinodis*) in addition to three medicinal plants (garlic, liquorice and ginger) intended to be used orally as a hepatosupportive and immunostimulant drug. The hepatoprotective effect of garlic extract is well documented in several recent studies [26]. Shenoy *et al.* [27] stated that the plant products are preferable due to their availability, safety and effectiveness as crude preparations.

Table 2. Serum biochemical parameters and inflammatory markers in control and different treated groups.

Parameters	Experimental groups							
	Acute study		Subchronic study			Chronic study		
	Control	Treated	Control	Low dose	High dose	Control	Low dose	High dose
AST (u/L)	41.6 ± 7.40	39.1 ± 5.84	48.7 ± 7.51	43.3 ± 7.10	52.7 ± 8.62	46.3 ± 5.51	42.3 ± 7.02	59.2 ± 6.17*
ALT (u/L)	46.8 ± 11.4	43.0 ± 15.1	37.7 ± 13.6	34.0 ± 6.25	34.7 ± 6.81	51.0 ± 5.00	44.3 ± 6.11	40.7 ± 7.64
Urea (mg/dl)	25.3 ± 6.08	33.8 ± 6.65	27.0 ± 4.58	29.0 ± 5.29	22.2 ± 2.46	27.7 ± 5.69	27.0 ± 3.61	26.8 ± 5.90
Creatinine (mg%)	0.31 ± 0.09	0.33 ± 0.10	0.70 ± 0.10	0.57 ± 0.12	0.67 ± 0.06	0.33 ± 0.06	0.40 ± 0.10	0.36 ± 0.08
Albumin (mg/dl)	2.92 ± 0.57	3.80 ± 0.25*	3.21 ± 0.60	3.93 ± 0.38	4.13 ± 0.97	3.13 ± 0.49	3.97 ± 0.87	3.80 ± 0.85
CRP (mg/L)	3.88 ± 0.18	3.60 ± 0.42	2.83 ± 0.97	2.50 ± 0.89	2.30 ± 0.56	2.60 ± 1.31	2.37 ± 0.97	2.87 ± 0.45
AFP (ng/ml)	4.10 ± 0.72	4.54 ± 0.49	3.67 ± 0.60	2.90 ± 0.57	6.10 ± 0.82*	3.81 ± 0.55	3.20 ± 0.82	5.49 ± 0.69*
TNF (ng/ml)	14.9 ± 4.03	12.5 ± 2.76	13.5 ± 0.91	12.3 ± 1.05	14.1 ± 1.14	13.1 ± 1.84	12.8 ± 1.75	14.3 ± 2.27

AST, aspartate aminotransferase; ALT, alanine aminotransferase; CRP, C-Reactive protein; AFP, α 1-fetoprotein; TNF, tumor necrosis factor. Data are expressed as means \pm SD (n = 5). Student's t-test was used. * $P \leq 0.05$ vs. control group was considered significant.

Table 3. Oxidant and antioxidant parameters in serum and liver of control and different treated groups.

Parameters	Experimental groups							
	Acute study		Subchronic study			Chronic study		
	Control	Treated	Control	Low dose	High dose	Control	Low dose	High dose
Serum MDA (nmol/ml)	2.26 ± 0.19	2.12 ± 0.31	2.34 ± 0.49	2.12 ± 0.47	2.42 ± 0.52	2.64 ± 0.43	2.42 ± 0.52	2.75 ± 0.61
Serum GSH (mg/dl)	10.50 ± 1.79	14.09 ± 4.09	10.55 ± 1.24	12.70 ± 1.84	13.70 ± 3.27	9.88 ± 1.18	13.07 ± 2.14	12.30 ± 1.51
liver MDA (nmol/g)	27.6 ± 3.36	24.4 ± 3.85	28.1 ± 3.33	26.1 ± 4.16	30.7 ± 4.85	26.4 ± 3.90	27.2 ± 4.44	34.4 ± 5.03*
liver GSH (mg/g)	41.1 ± 6.83	42.3 ± 7.58	44.1 ± 8.11	52.9 ± 9.53	40.9 ± 7.01	10.8 ± 1.42	9.86 ± 1.56	7.75 ± 1.44*

MDA, malondialdehyde; GSH, reduced glutathione. Data are expressed as means \pm SD (n = 5). Student's t-test was used. * $P \leq 0.05$ vs. control group was considered significant.

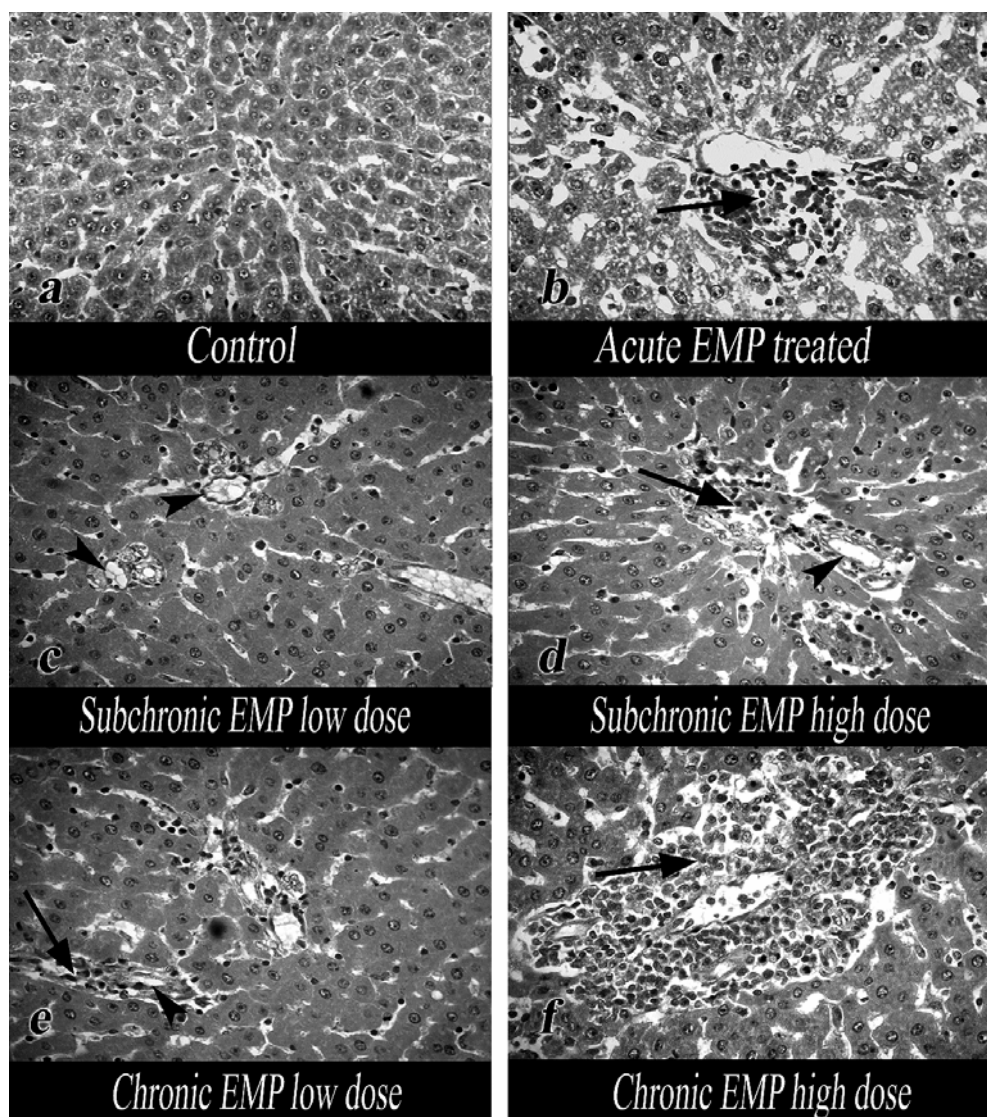


Figure 1. Liver treated with EMP showing dose-dependent lesions: Leukocytic infiltrations (arrows); mild hyperplasia of bile ducts (arrow heads). H&E. X 400.

Evaluation of median lethal dose aimed to assess the acute toxicity of the new medicinal preparation, where our results confirmed that there were no signs of toxicity or deaths within 24 h after oral administration of EMP up to the highest possible dose (5 g/kg b.wt.) Furthermore, there were no delayed signs of toxicity up to 14 days post EMP oral administration. Many researchers considered substances and drugs as non-toxic compounds if their LD₅₀ is higher than 5 g/kg b.wt. [28].

Different chronological studies of the toxic effects of the EMP preparation were evaluated in

rats by estimating the hematological and the serum biochemical parameters along with the histological examination of liver and kidney tissues.

Except for AST and albumin, the present results revealed non-significant effect of EMP on the hematological and other examined biochemical parameters. Only after the administration of a high dose of EMP for 3 months, the AST level was significantly increased by about 1.5 folds. The AST elevation in rat sera in our study can be attributed to a limited membrane leakage due to hepato-cellular damage [29]. While the AST is a

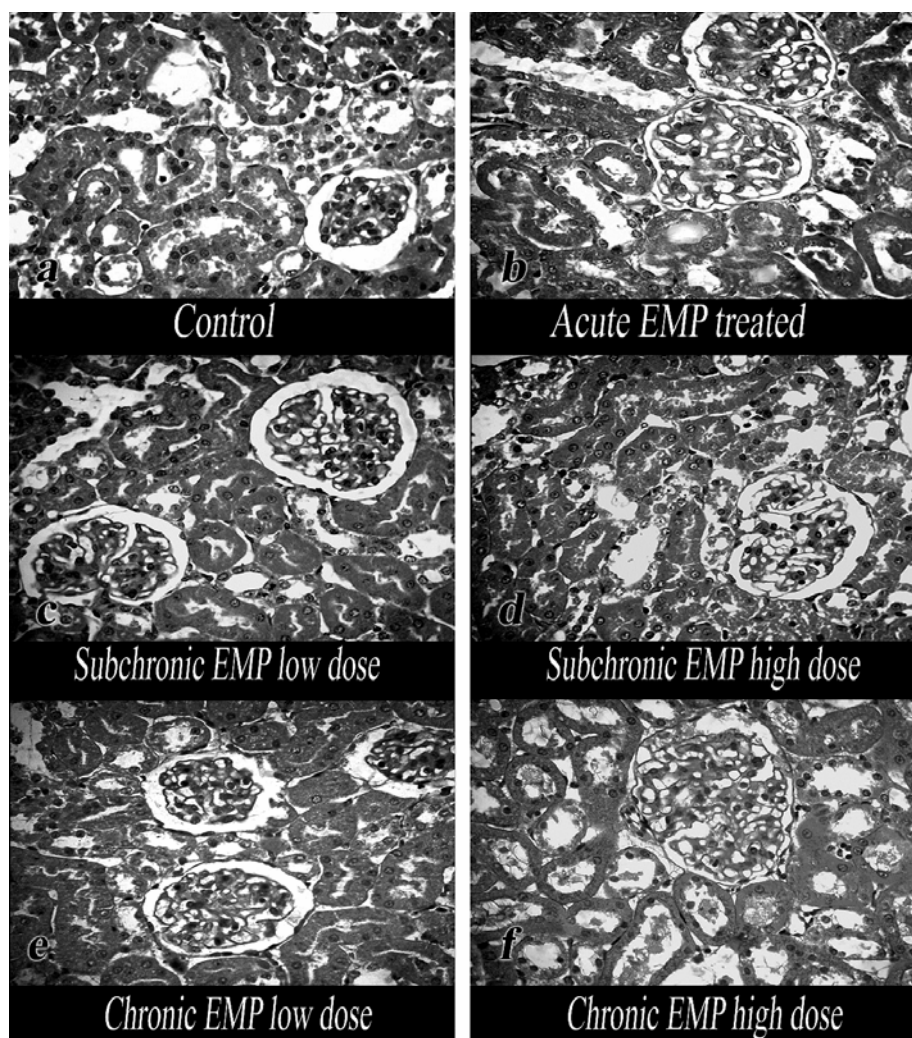


Figure 2. Kidney treated with EMP showing dose-dependent lesions: Mild tubular degenerative changes and mild hyperplasia of glomeruli. H&E. X 400.

sensitive indicator for liver injury, this 1.5-fold elevation is only considered as a mild elevation (<2-3 folds) as stated by Flora *et al.* [30]. Besides, many FDA-approved drugs show transient AST and ALT elevation by 2 or more folds [31].

The ALT level increases above that of AST in inflammatory conditions, while the AST exceeds the ALT levels in case of cellular damage and necrosis [7].

Blood albumin concentrations were elevated by EMP administration in all treated groups; this elevation was only significant in acute study. Albumin is a multifunction protein; its core function is to regulate the oncotic pressure, besides

its role as an antioxidant, immunomodulator, detoxificant and transporter protein. These functions are impaired during some diseases, particularly liver and kidney disorders [32]. Comparable increase in serum albumin was noted by our research team when ethanolic extract of the brown algae (*Sargassum dentifolium*) was orally administered in carbon tetrachloride-induced hepatitis in rats [7].

There were no significant alterations in the tested CRP and TNF inflammatory markers, while there was a significant increase in AFP level in the high dose-treated groups after one and three months of the beginning of the experiment. α 1-fetoprotein (AFP) is normally produced by the fetus liver and

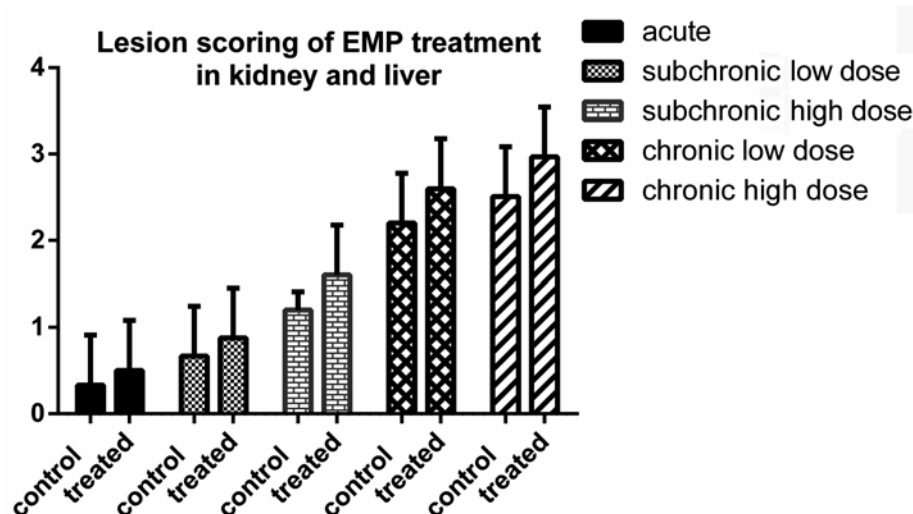


Figure 3. Semiquantitative scoring of hepatic and renal lesions; the histopathological scoring was performed according to Gibson-Corley *et al.* [24].

yolk sac and should only be found in adults in very low levels. It is one of tumor markers that is found mainly in liver cancer and in some cases of cirrhosis or chronic active hepatitis [33].

The current results revealed that the administration of EMP at a high dose for three months increased lipid peroxidation through the rise of hepatic MDA and decrease of GSH antioxidant activity in liver. These effects provoke hepatic oxidative stress and toxicity [2]. The histological examination revealed mild effects on liver and kidney but treatment with high dose of EMP for 3 months showed moderate hyperplasia of bile ducts, mononuclear leucocytic infiltrations and focal hydropic degeneration of hepatocytes as well as focal mild degeneration of renal tubules with the presence of homogenous eosinophilic materials in their lumen, moderate expansion of some glomeruli with vacuolation and proliferation of capillary endothelium. There were no significant differences between lesion scores of both liver and kidney in all treated groups compared to control groups. Gazor *et al.* [34] stated that *C. trinodis* produced glomerular congestion, hyaline cast and severe interstitial inflammatory centers in kidney when administered at a dose of 5, 10, 15, 25 and 50 mg/kg for two weeks.

Many studies proved that the brown algae have antioxidant, antiulcer, anticancer, antifungal and antibacterial effects [35-38, 10].

EMP extract contains several phytoconstituents that have antioxidant and anti-inflammatory activities such as alkaloids, saponins, flavanoids, tannin and steroids; thus the selected plants are known by their beneficial effects [11]. Based on our histopathological assessment, the EMP could have some adverse effects on liver and kidney at high doses, mostly for long duration. These adverse effects were in dose- and time-dependent manners.

CONCLUSION

In conclusion, the tested EMP may be safe and even beneficial in small doses for one or two months, but further investigations are required to determine the safest dose and duration, as well as the ideal ratio between its constituents.

CONFLICT OF INTEREST STATEMENT

All authors declare that there are no conflicts of interest related to this manuscript. This research is self-funded; we had no funding grants from any governmental or non-governmental organizations or institutes.

REFERENCES

1. Vadlapudi, V. 2012, Antioxidant Activities of Marine Algae, Research Signpost, Kerala, India, 189-203.
2. Abdou, R. H., Saleh, S. Y. and Khalil, W. F. 2015, Pharmacogn. Mag., (Suppl. 1), 93-101.

3. Frishman, W. H., Beravol, P. and Carosella, C. 2009, *Dis. Mon.*, 55, 121-192.
4. Kang, C. G., Hah, D. S., Kim, C. H., Kim, Y. H., Kim, E. and Kim, J. S. 2011, *Toxicol. Res.*, 27, 31-36.
5. Pan, S. Y., Zhou, S. F., Gao, S. H., Yu, Z. L., Zhang, S. F., Tang, M. K., Sun, J. N., Ma, D. L., Han, Y. F., Fong, W. F. and Ko, K. M. 2013, *Evid. Based Complement. Alternat. Med.*, 627375.
6. El Shafay, S. M., Ali, S. S. and El-Sheekh, M. M. 2016, *Egypt. J. Aquat. Res.*, 42, 65-74.
7. Madkour, F. F., Khalil, W. F. and Dessouki, A. A. 2012, *Int. J. Pharm. Pharm. Sci.*, 4 (3), 637-641.
8. Morrissey, J., Kraan, S. and Guiry, M. D. 2001, *A Guide to Commercially Important Seaweeds on the Irish Coast*, Dublin, Bord Iascaigh Mhara/Irish Fisheries Board, 5-40.
9. Smit, A. J. 2004, *J. Appl. Phycol.*, 16, 245-262.
10. Tajbakhsh, S., Ilkhani, M., Rustaiyan, A., Larijani, K., Sartavi, K., Tahmasebi, R. and Asayesh, G. 2011, *J. Med. Plants Res.*, 5(18), 4654-4657.
11. Madkour, F. F., Hassan, M. M., Khalil, W. F. and Abdo, W. 2013, *J. Adv. Vet. Res.*, 3(3), 102-108.
12. Michael, A. 2013, *A Dictionary of Plant Science*. 3rd Ed., Oxford University Press, 340.
13. Bruce, R. D. 1957, *Fundam. Appl. Toxicol.*, 8, 97-100.
14. Reitman, S. and Frankel, S. 1957, *Am. J. Clin. Pathol.*, 28, 56-63.
15. Tietz, N. W. 1995, *Clinical Guide to Laboratory Tests*. 3rd Ed. Philadelphia, 22-34.
16. Larsen, K. 1972, *Clin. Chim. Acta*, 41, 209-217.
17. Coulombe, J. J. and Favreau, L. 1963, *Clin. Chem.*, 9, 102-108.
18. Mihara, M. and Uchiyama, M. 1978, *Anal. Biochem.*, 86, 271-278.
19. Beutler, E., Duron, O. and Kelly, M. B. 1963, *J. Lab. Clin. Med.*, 61, 882-888.
20. Cuckle, H. S., Wald, N. J. and Thompson, S. G. 1987, *Br. J. Obstet. Gynaecol.*, 94, 387-402.
21. Macy, E. M., Hayes, T. E. and Tracy, R. P. 1997, *Clin. Chem.*, 43(1), 52-58.
22. Pasparakis, M., Alexopoulou, L., Episkopou, V. and Kollias, G. 1996, *J. Exp. Med.*, 184, 1397-1411.
23. Bancroft, J. D. and Stevens, A. 1996, *The haematoxylin and eosin. Theory and practice of histological techniques*. Churchill Livingstone, London, New York & Tokyo. 4th Ed., 99-112.
24. Gibson-Corley, K. N., Olivier, A. K. and Meyerholz, D. K. 2013, *Vet. Pathol.*, 50(6), 1007-1015.
25. Snedecor, G. and Cochran, W. 2014, *Statistical Methods* 8th Ed., Ames. Iowa State University.
26. Shin, J. H., Lee, C. W., Oh, S. J., Yun, J., Kang, M. R., Han, S. B., Park, H., Jung, J. C., Chung, Y. H. and Kang, J. S. 2014, *Toxicol. Res.*, 30, 49-54.
27. Shenoy, C., Patil, M. B., Kumar, R. and Patil, S. 2009, *Int. J. Pharm. Pharm. Sci.*, 2(2), 167-175.
28. Hodge, H. C., Sterner, J. H. 1956, *Handbook of Toxicology*, W. S. Spector (Ed.), Philadelphia W. B. Saunders Company, 37.
29. Abdou, R. H., Basha, A. W. and Khalil, W. F. 2019, *Toxicol. Res.*, 35(3), 233-239.
30. Flora, K. D. and Keeffe, E. B. 1990, *J. Insur. Med.*, 22(3), 206-210.
31. Lee, J., Kim, D., Seo, J., Lee, H., Oh, J., Shin, H., Yoon, S. J. and Kim, C. 2008, *Toxicol Res.*, 24, 289-295.
32. Garcia-Martinez, R., Caraceni, P., Bernardi, M., Gines, P., Arroyo, V. and Jalan, R. 2013, *Hepatology*, 58(5), 1836-1846.
33. Ertle, J. M., Heider, D., Wichert, M., Keller, B., Kueper, R., Hilgard, P., Gerken, G. and Schlaak, J. F. 2013, *Digestion*, 87(2), 121-131.
34. Gazor, R., Pasharan, A., Almasi, S. and Ghasemi, S. 2016, *Pharm. Sci.*, 22, 49-53.
35. Mori, J., Hayashi, T., Iwashima, M., Matsunaga, T. and Saito, H. 2006, *Biol. Pharm. Bull.*, 29(6), 1197-1201.
36. Lekameera, R., Vijayabaskar, P. and Somasundaram, S. T. 2008, *Afr. J. Food Sci.*, 2(11), 126-130.
37. Farshadpour, F. and Sartavi, K. 2010, *Eur. Rev. Med. Pharmacol. Sci.*, 14(8), 669-673.
38. Taskin, E., Caki, Z., Ozturk, M. and Taskin, E. 2010, *Afr. J. Biotechnol.*, 9(27), 4272-4277.